

# Matrix Metalloproteinase 2 Is Associated With Stable and Matrix Metalloproteinases 8 and 9 With Vulnerable Carotid Atherosclerotic Lesions

## A Study in Human Endarterectomy Specimen Pointing to a Role for Different Extracellular Matrix Metalloproteinase Inducer Glycosylation Forms

Joost P.G. Sluijter, PhD; Wilco P.C. Pulskens, MSc; Arjan H. Schoneveld, BSc; Evelyn Velema, BSc; Chaylendra F. Strijder, BSc; Frans Moll, MD; Jean-Paul de Vries, MD; Jan Verheijen, PhD, MD; Roeland Hanemaaijer, MD; Dominique P.V. de Kleijn, PhD; Gerard Pasterkamp, PhD, MD

**Background and Purpose**—We studied matrix metalloproteinases (MMP) 2, 8, and 9 and extracellular matrix metalloproteinase inducer (EMMPRIN) levels in relation to carotid atherosclerotic plaque characteristics.

**Methods**—Carotid atherosclerotic plaques (n=150) were stained and analyzed for the presence of collagen, smooth muscle cell (SMC), and macrophages. Adjacent segments were used to isolate total protein to assess MMP-2 and MMP-9 activities and gelatin breakdown, MMP-8 activity, and EMMPRIN levels.

**Results**—Macrophage-rich lesions revealed higher MMP-8 and MMP-9 activities, whereas SMC-rich lesions showed higher MMP-2 activity. The levels of less glycosylated EMMPRIN-45kD were higher in SMC-rich lesions and lower in macrophage-rich plaques. EMMPRIN-45kD was associated with MMP-2 levels, whereas EMMPRIN-58kD was related to MMP-9 levels.

**Conclusions**—MMP-2, MMP-8, and MMP-9 activities differed among carotid plaque phenotypes. Different EMMPRIN glycosylation forms are associated with either MMP-2 or MMP-9 activity, which suggests that EMMPRIN glycosylation may play a role in MMP regulation and plaque destabilization. (*Stroke*. 2006;37:235-239.)

**Key Words:** atherosclerosis ■ carotid arteries ■ carotid artery plaque ■ endarterectomy ■ inflammation ■ matrix metalloproteinases

Atherosclerosis is characterized by remodeling of the extracellular matrix and the accumulation of lipids and inflammatory cells.<sup>1</sup> Advanced stable atherosclerotic plaques are rich in collagen and smooth muscle cells (SMCs), whereas a large lipid core covered by a thin fibrous cap with a dense inflammatory infiltrate characterizes unstable and ruptured plaques.<sup>2</sup> Increased expressions of matrix metalloproteinases (MMPs) 1, 2, 3, 7, 8, 9, and 13 are found in macrophages and in SMCs covering the shoulder regions of atherosclerotic plaques.<sup>3</sup>

Extracellular MMP inducer (EMMPRIN) stimulates the production of different MMPs.<sup>4</sup> EMMPRIN has been identified in human macrophage-rich atheroma.<sup>5</sup> However, the relation of EMMPRIN with plaque characteristics and MMP expression remains to be elucidated. In the present study, carotid endarterectomy plaque characteristics were associated

with MMP-2, MMP-8, and MMP-9 activities and EMMPRIN expression levels.

### Methods

Athero-Express is an ongoing multicenter study in which carotid atherosclerotic specimen are obtained from patients undergoing endarterectomy.<sup>6</sup> Segments of the culprit lesion of each plaque were studied semiquantitatively for collagen content, SMCs, and macrophages and classified as no/minor or moderately/heavily stained. Moreover, an overall plaque phenotype was assigned to each lesion based on overall appearance.

The adjacent segment was used to isolate total protein and MMP-2, MMP-8, and MMP-9. Total MMP activities were measured using the Biotrak activity assays RPN2631, RPN2635, and RPN2634, respectively (Amersham Biosciences). To determine pro- and active MMP-2 and MMP-9 levels in each plaque, zymography was performed as described elsewhere.<sup>7</sup> EMMPRIN expression levels were determined by Western blotting (sc-9753, Santa Cruz Biotechnology).

Received August 17, 2005; final revision received October 6, 2005; accepted October 21, 2005.

From the Experimental Cardiology Laboratory (J.P.G.S., W.P.C.P., A.H.S., E.V., C.F.S., D.P.V.d.K., G.P.) and Vascular Surgery (F.M.), University Medical Center, Utrecht; Interuniversity Cardiology Institute of the Netherlands (J.P.G.S., A.H.S., D.P.V.d.K.), Utrecht; Vascular Surgery (J.P.d.V.), Nieuwegein; and Biomedical Research (J.V., R.H.), The Netherlands Organization for Applied Scientific Research (TNO), Leiden, the Netherlands.

Correspondence to Gerard Pasterkamp, MD, PhD, University Medical Center, Experimental Cardiology Laboratory, Heidelberglaan 100, Room G02-523, 3584 CX Utrecht, the Netherlands. E-mail g.pasterkamp@hli.azu.nl

© 2005 American Heart Association, Inc.

Stroke is available at <http://www.strokeaha.org>

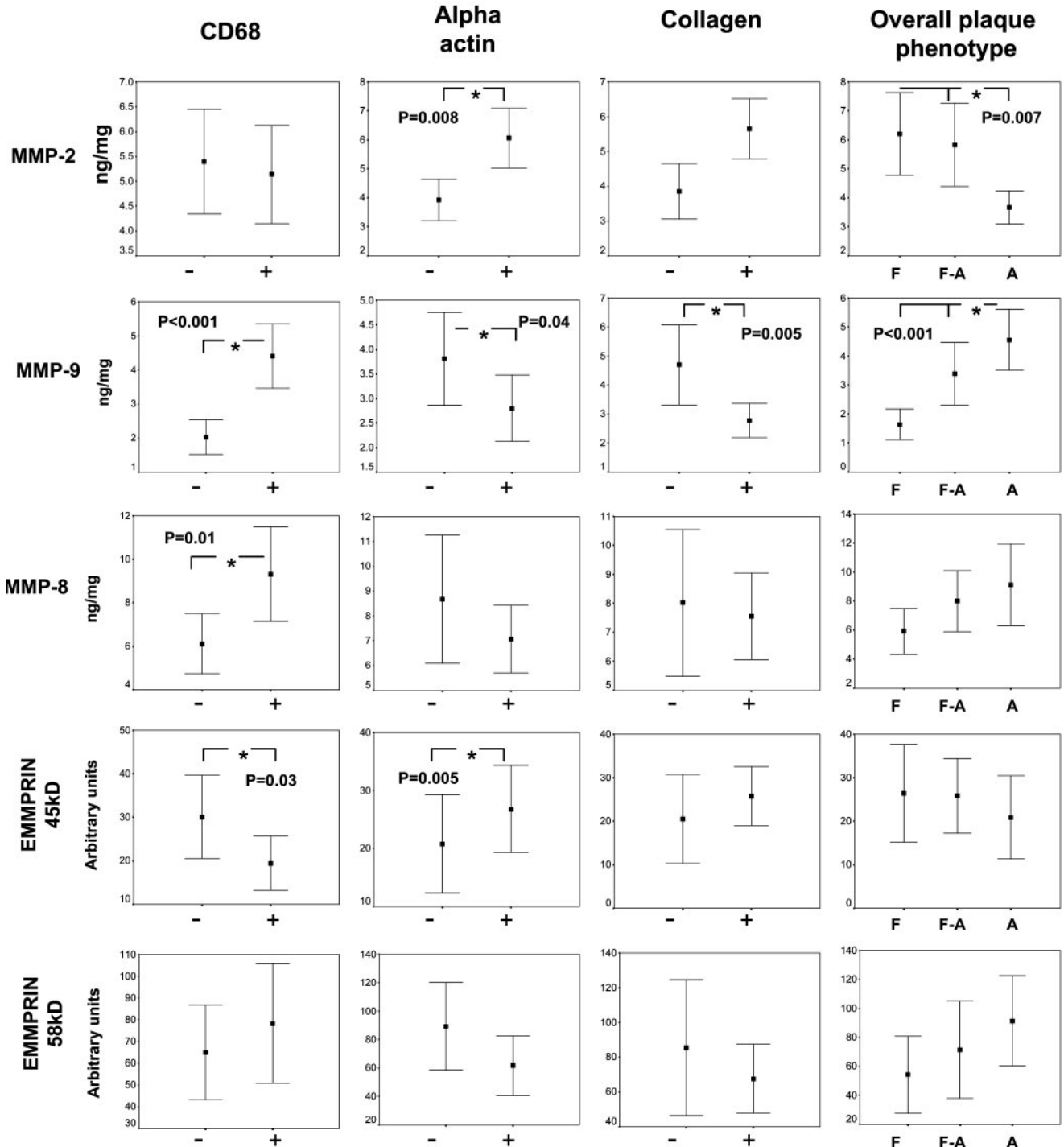
DOI: 10.1161/01.STR.0000196986.50059.e0

Human SMCs (CRL-1999, American Type Culture Collection) and monocytes (THP-1 and TIB-202, American Type Culture Collection) were cultured according to the manufacturer. Total cell protein was isolated by using Tripure Isolation Reagent (Boehringer Mannheim), and EMMPRIN expression and MMP activity were studied.

Data are presented as mean and 95% CI. One-way ANOVA, Mann-Whitney test, or Kruskal-Wallis test was used to compare differences among histological sections and EMMPRIN with MMP levels. *P* values of <0.05 were considered significant.

**Results**

MMP-9 levels were increased in atheromatous plaques and in plaques that revealed more CD68, less  $\alpha$ -actin, and less collagen staining (Figure 1). MMP-8 activity levels were increased in plaques that revealed more CD68 staining. In contrast, MMP-2 activity levels were increased in fibrous plaques and in plaques with more SMC staining. Regression analysis among MMP-2, MMP-8, and MMP-9 levels showed



**Figure 1.** MMP and EMMPRIN expression levels in sections stained for CD68 (macrophages),  $\alpha$ -actin (SMCs), collagen, and the overall phenotype of the plaque. (Data in mean and 95% CI. \**P*<0.05; -=no/minor staining, +=moderate/heavy staining; F=fibrous, F-A=fibroatheromatous, and A=atheromatous).

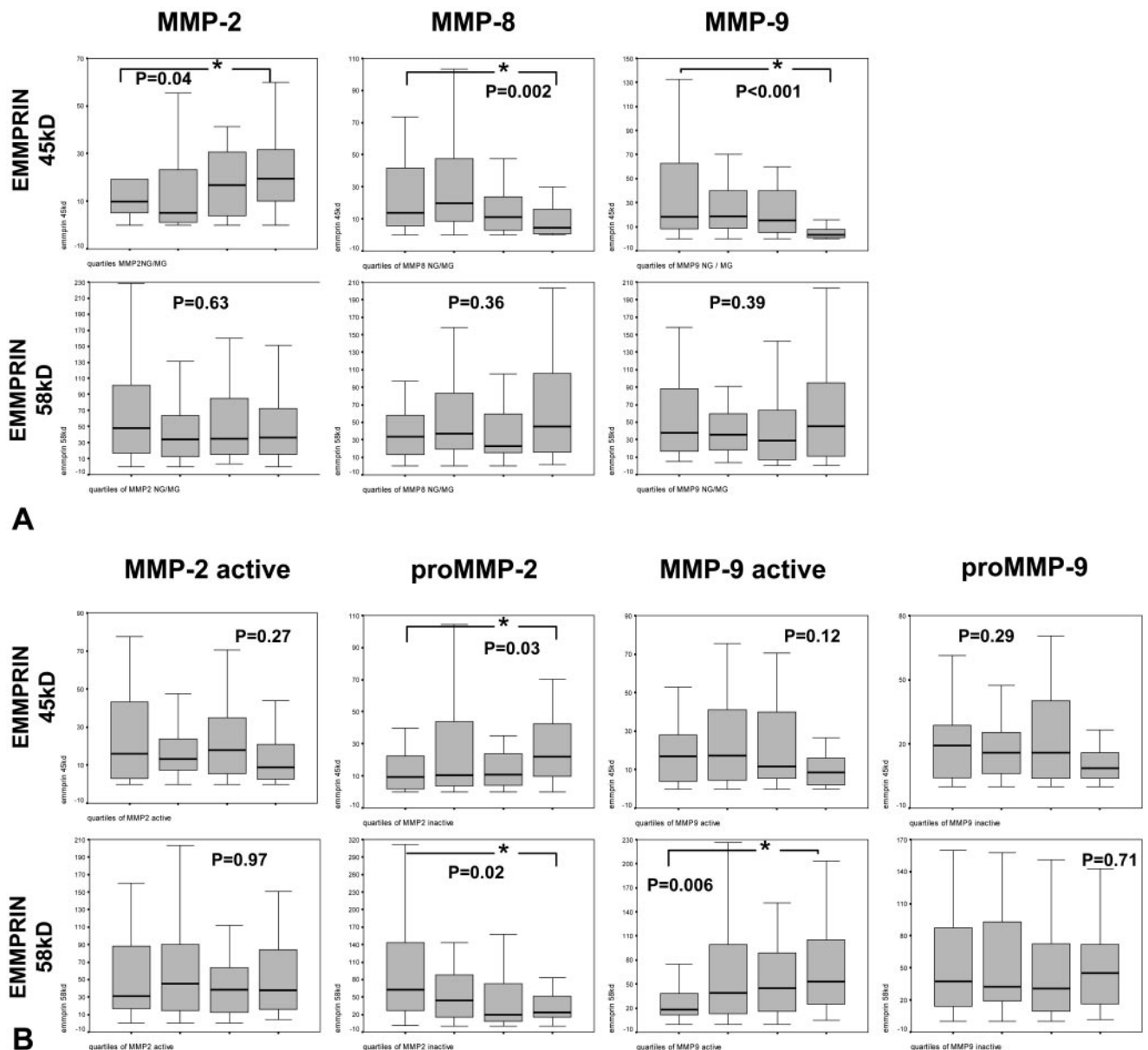
a relation between MMP-8 and MMP-9 ( $r=0.59$ ,  $B=1.38$ ,  $P<0.001$ ).

Higher EMMPRIN-45kD levels were observed in sections heavily stained for SMC, but lower EMMPRIN-45kD expression levels were found in macrophages-rich sections. No differences in EMMPRIN-58kD levels were observed between groups.

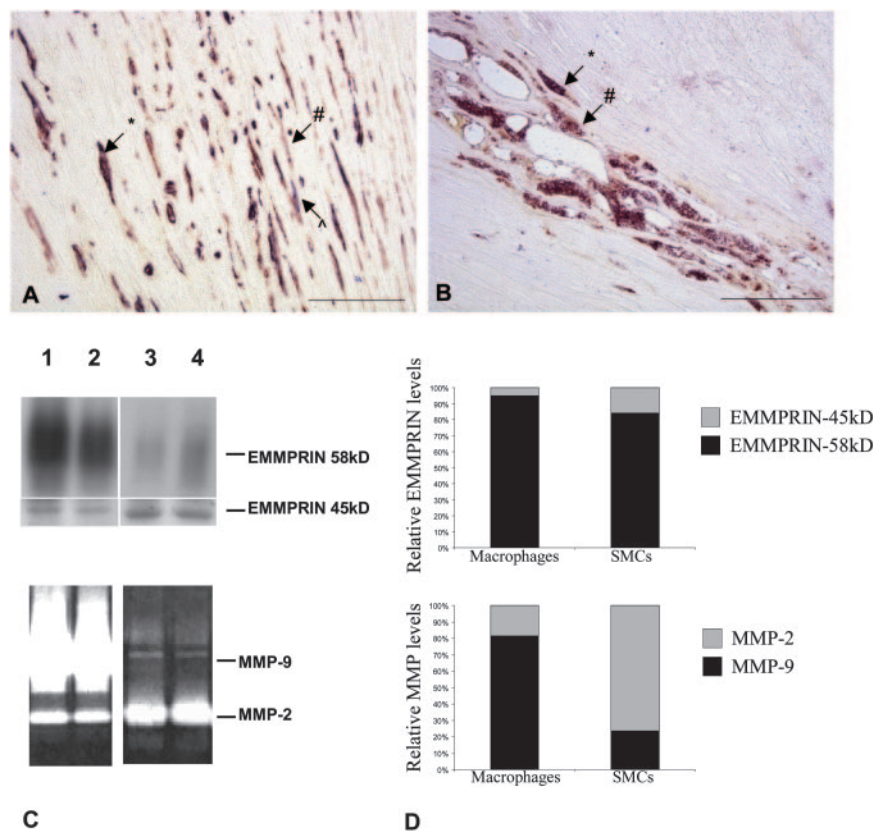
EMMPRIN has been reported to induce MMP expression and not MMP activation directly. Therefore, we studied the relation between EMMPRIN levels not only with MMP activity levels but also with the amount of gelatin breakdown of the individual active and inactive MMP-2 and MMP-9 levels obtained by zymography. Regression analysis between both MMP methods revealed a consistent expression pattern and comparable plaque results (data not shown).

A significant relation was observed between EMMPRIN-45kD and MMP-2, and an inverse relation was observed with MMP-8 and 9 activity levels (Figure 2). Also, a significant correlation between EMMPRIN-45kD and gelatin breakdown by pro-MMP-2 levels was detected. EMMPRIN-58kD was inversely associated with gelatin breakdown by pro-MMP-2 and with active MMP-9, as determined by zymography (Figure 2).

Immunoreactivity to EMMPRIN in the atherosclerotic lesions was observed in both macrophage-rich and SMC-rich areas (Figure 3A and 3B). This was confirmed on cell lysates of cultured SMCs and macrophages (Figure 3C). Interestingly, macrophages contained relatively more EMMPRIN-58kD and MMP-9, whereas SMCs produced more EMMPRIN-45kD and MMP-2 (Figure 3D), confirming the observations in atherosclerotic plaques.



**Figure 2.** Correlations between EMMPRIN-45kD and -58kD and (A) quantitative MMP activity levels, or (B) gelatin breakdown by active and inactive MMP bands, as determined by zymography (\* $P<0.05$ ). Continuous MMP variables were categorized into percentile groups (quartiles) and plotted against EMMPRIN expression.



**Figure 3.** Immunohistochemical double stainings (\*, purple) for (A) CD68 (#, red) and EMMPRIN (♣, blue), and for (B) SMCs (#, red) and EMMPRIN (♣, blue) in atherosclerotic lesions (bar=500  $\mu$ m). (C) EMMPRIN (Western blot) and MMP expression (zymography) in cultured macrophages (lanes 1 and 2) and SMCs (lanes 3 and 4). (D) Quantitative analysis of EMMPRIN and MMP expression (n=3).

## Discussion

We demonstrated previously that unstable plaque characteristics are associated with clinical symptoms.<sup>6</sup> Here, we observed that MMP-2, MMP-8, and MMP-9 activities differed among carotid plaque phenotypes. Previous studies observed that MMP-9 immunostaining mostly colocalizes with macrophages<sup>3,7</sup> and relates to unstable carotid plaques.<sup>8</sup> Our results confirm the association between MMP-9 and an unstable plaque type. Because intact collagens are not substrates for MMP-9, this enzyme cannot be solely responsible for plaque rupture. Recently, increased MMP-8 activity was observed in unstable carotid plaques colocalized with CD68 positive cells.<sup>9</sup> Here we confirmed the association among MMP-8, MMP-9, and an inflammatory plaque phenotype.

We observed previously a more diffuse staining throughout the atherosclerotic plaque for MMP-2 not specifically colocalized with macrophages and that both MMP-2 and MMP-9 immunoreactivity were more prevalent in expansively remodeled plaques,<sup>7</sup> associated with unstable angina.<sup>10</sup> However, in the present study, a large number of specimens was studied showing a clear differentiation in MMP-2 expression among plaque phenotypes. Increased MMP-2 activity levels were associated with SMC presence and a fibrous phenotype, suggesting that MMP-2 expression is associated with a stable lesion phenotype.

Different forms of EMMPRIN can be produced by different modes of glycosylation,<sup>11</sup> but it remains to be elucidated how glycosylation can regulate its induction capacity. In the present study, EMMPRIN-45kD expression levels correlated with the presence of SMC, whereas EMMPRIN-58kD was

expressed by both macrophages and SMCs but more abundantly by macrophages. Furthermore, both EMMPRIN forms were associated with different MMP expression patterns. This suggests that different cell types produce different amounts of EMMPRIN-45kD and -58kD, resulting in a different MMP repertoire. Preliminary analysis revealed a trend to decreased EMMPRIN-45kD and increased EMMPRIN-58kD levels in patients with clinical symptoms (data not shown).

In conclusion, MMP-8 and MMP-9 activity levels are increased in more unstable plaques, whereas MMP-2 activity levels are higher in stable lesions. MMP expressions were associated with differently glycosylated EMMPRIN forms. Differences in EMMPRIN forms are also observed among plaque phenotypes; therefore, EMMPRIN may play a role in MMP regulation and plaque destabilization.

## Acknowledgments

This work is supported by the Netherlands Organization for Scientific Research grants 902-16-239, 902-26-213, and 902-16-222 and the Netherlands Heart Foundation grant 99-209.

## References

- Ross R. Atherosclerosis—an inflammatory disease. *N Engl J Med*. 1999; 340:115–126.
- Virmani R, Kolodgie FD, Burke AP, Farb A, Schwartz SM. Lessons from sudden coronary death: a comprehensive morphological classification scheme for atherosclerotic lesions. *Arterioscler Thromb Vasc Biol*. 2000; 20:1262–1275.
- Galis ZS, Sukhova GK, Lark MW, Libby P. Increased expression of matrix metalloproteinases and matrix degrading activity in vulnerable regions of human atherosclerotic plaques. *J Clin Invest*. 1994;94: 2493–2503.

4. Guo H, Zucker S, Gordon MK, Toole BP, Biswas C. Stimulation of matrix metalloproteinase production by recombinant extracellular matrix metalloproteinase inducer from transfected Chinese hamster ovary cells. *J Biol Chem*. 1997;272:24–27.
5. Major TC, Liang L, Lu X, Rosebury W, Bocan TM. Extracellular matrix metalloproteinase inducer (EMMPRIN) is induced upon monocyte differentiation and is expressed in human atheroma. *Arterioscler Thromb Vasc Biol*. 2002;22:1200–1207.
6. Verhoeven BAN, Hellings WE, Moll FL, de Vries JPPM, de Kleijn DPV, de Bruin P, Busser E, Schoneveld AH, Pasterkamp G. Carotid atherosclerotic plaques in patients with TIA and Stroke have unstable characteristics compared to plaques in asymptomatic and amaurosis fugax patients. *J Vasc Surg*. In press.
7. Pasterkamp G, Schoneveld AH, Hijnen DJ, de Kleijn DP, Teepen H, van der Wal AC, Borst C. Atherosclerotic arterial remodeling and the localization of macrophages and matrix metalloproteases 1, 2 and 9 in the human coronary artery. *Atherosclerosis*. 2000;150:245–253.
8. Loftus IM, Naylor AR, Goodall S, Crowther M, Jones L, Bell PR, Thompson MM. Increased matrix metalloproteinase-9 activity in unstable carotid plaques. A potential role in acute plaque disruption. *Stroke*. 2000;31:40–47.
9. Molloy KJ, Thompson MM, Jones JL, Schwalbe EC, Bell PR, Naylor AR, Loftus IM. Unstable carotid plaques exhibit raised matrix metalloproteinase-8 activity. *Circulation*. 2004;110:337–343.
10. Pasterkamp G, Schoneveld AH, van der Wal AC, Haudenschild CC, Clarijs RJ, Becker AE, Hillen B, Borst C. Relation of arterial geometry to luminal narrowing and histologic markers for plaque vulnerability: the remodeling paradox. *J Am Coll Cardiol*. 1998;32:655–662.
11. Kanekura T, Miyauchi T, Tashiro M, Muramatsu T. Basigin, a new member of the immunoglobulin superfamily: genes in different mammalian species, glycosylation changes in the molecule from adult organs and possible variation in the N-terminal sequences. *Cell Struct Funct*. 1991;16:23–30.